

***Hibiscus sabdariffa* Aqueous Extracts Prevents Progression of Acute Liver Injury Induced by Acetaminophen**

Ahmad-Raus, R.^{1*}, Jamal, P.¹ and Mohd-Isa, E. S.²

¹Department of Biotechnology Engineering, Kulliyah of Engineering, International Islamic University of Malaysia, Jalan Gombak, 51100 Kuala Lumpur, Malaysia

²Department of Biomedical Sciences, Faculty of Allied Health Sciences, Universiti Kebangsaan Malaysia, Jalan Raja Muda Abdul Aziz, 50300 Kuala Lumpur, Malaysia

ABSTRACT

Hibiscus sabdariffa (local name Roselle) is usually used as a beverage in Southeast Asia. It has been shown that this plant has benefits to the health in term of improving diabetes and hiperlipidemia conditions. In this study, the effect of *H. sabdariffa* aqueous extracts in preventing acute liver injury progression in rats induced by acetaminophen (or paracetamol, PCM) was investigated. Results of the current study showed that intravenous injection of PCM at 1000 mg/kg induced lipid proxidation (malonaldehyde, MDA) and deteriorated liver marker enzymes (alanin transaminase, ALT and glutathione S-transferase, GST), as well as liver glutathione (GSH) and liver morphology. Feeding *H. sabdariffa* extract orally (500 or 1000 mg/kg) for three days after the PCM treatment was found to have significantly reduced lipid peroxidation. The depleted GSH observed in the affected liver returned to almost normal, while the liver marker enzyme, ALT and GST levels were improved by giving the extract. In histological examination, the *H. sabdariffa* extract was shown to have reduced the incidence of liver damage. However, a high dose of *H. sabdariffa* treatment to the untreated rats increased liver MDA and GST and serum ALT levels, although at a much lower level than the PCM-treated rats. Hence, the liver histology of these rats remains normal. In conclusion, the current study has shown that the post-treatment of *H. sabdariffa* prevents the progression of acute liver damage induced by PCM. However, the consumption of the plant at high dosage should be taken with caution.

ARTICLE INFO

Article history:

Received: 2 May 2010

Accepted: 31 January 2011

E-mail addresses:

rahaar@iiu.edu.my (Ahmad-Raus, R.), jparveen@iiu.edu.my (Jamal, P.)

* Corresponding author

Keywords: *Hibiscus sabdariffa*, paracetamol, liver toxicity, MDA, GSH, GST, ALT

INTRODUCTION

Hibiscus sabdariffa or roselle is also known as *asam paya*, *asam keling*, *asam susur* or

asam belanda, and it can be found in Asian and African tropical forests. Lately, it was planted in big scale in Malaysia for its calyx to make juice, syrup, jam, marmalade and chutney. Calyx is part of the plant's flower that enlarges and turns into fleshy and juicy structures once the flower wilts. Nutritional values of the calyx have long been established (Mat Isa, 1985). It is rich in vitamin C and also contains vitamins D, B1, B2 and B complex. Interestingly in some countries, their uses are not restricted to food industries only, as they are also used in traditional medicine to treat certain diseases. In India, Africa and Mexico, all the above-ground parts of the roselle plant are used in native medicine. Infusions of the leaves or calyces are regarded as diuretic, cholorectic, febrifugal, hypotensive, and can decrease the viscosity of blood, reduce fats in blood and stimulate intestinal peristalsis (Morton, 1987).

Some of these claims are proven to be true through scientific findings. Some recent studies have demonstrated that *H. sabdariffa* significantly reduced blood pressure in experimental animals (Ajay *et al.*, 2007) and humans (Herrera-Arellano *et al.*, 2004). In 1991, el-Saadany and colleagues confirmed the hypocholesterolemic activity of the plant when they observed lowering effect in the different lipid fraction levels of hypercholesterolemic rat. The continuous interests in this plant up to now have led to many scientific discoveries that exceed the traditional medicinal belief. One of them is the ability of the plant extract to protect

liver from acute injury. In various studies, pre-treatment of *H. sabdariffa* extract to animals suffering from liver injury induced by tert-butylhydroperoxide (t-BHP), lipopolysaccharide and azathioprine (Liu *et al.*, 2002; Lin *et al.*, 2003; Amin & Hamza, 2005) was found to have blocked the elevated levels of liver marker enzymes (alanine aminotransferase, ALT and aspartate aminotransferase, AST) and improved the abnormality of liver histology. In addition, the extract also has the capability to protect liver from radiation (Adaramoye *et al.*, 2008) and counteract the over-dosage effect of acetaminophen (paracetamol, PCM) (Olaleye *et al.*, 2010; Rocha, 2008). All these studies, however, showed that the liver damage could be reduced if one consumed *H. sabdariffa* before the occurrence of the damage. Conversely in this study, the researchers purposely damaged the liver through a treatment of excess PCM before supplementing the animals with *H. sabdariffa* aqueous extract. This was done to investigate whether *H. sabdariffa* extract would be able to prevent acute liver injury progression induced by the damaging agent. The effects of *H. sabdariffa* to a normal liver were also determined. To achieve these, the levels of liver marker enzymes, alanin transaminase (ALT) and glutathione S-transferase (GST), plus malonaldehyde (MDA) and glutathione (GSH), were investigated. In addition, the morphological changes of liver histology were also investigated.

MATERIALS AND METHODS

Animals and Diets

Thirty-six male *Sprague dawley* rats, weighing 190-200 g, were used in the experiment. They were given commercial rat pellets (Gold Coin Company, Malaysia) and water on a daily basis. The animals were equally divided into six groups, i.e. the untreated (control), PCM-treated (hepatotoxicity animals), low *H. sabdariffa* plus PCM diet-treated, high *H. sabdariffa* plus PCM diet-treated, as well as low and high *H. sabdariffa* diet-treated groups.

The control group was given the commercial rat chow diet throughout the experiment. Liver toxicity was induced in the animals by giving 1000 mg/kg body weight animal PCM intraperitoneally. The mixed diet- and low and high *H. sabdariffa* diet-treated groups were given 500 and 1000 mg/kg body weight animal *H. sabdariffa* extract, respectively. It was given orally once for three consecutive days. For the mixed diet-treated animals, the extract was given after the PCM injection. The extract was prepared according to the method of Azuine *et al.* (1992). Dried *H. sabdariffa* calyx used in the preparation of the extract was supplied by Monroe Company Sendirian Berhad, Kuala Lumpur.

Collections of Serum and Liver

After 72 hours of the treatment, the animals were fasted overnight in preparation for the serum and liver collections. In the morning, the animals were weighed and anesthetized under chloroform, while the

thoracic abdominal cavity was opened. Blood was collected by heart puncture and serum was separated by centrifugation of the blood. The liver was excised from each animal and washed with 1.15% cold calcium chloride to remove the blood stain. The liver was weighed and a small section of the liver was fixed in 10% (v/v) formalin solution for hematoxylin and eosin (H & E) staining. 750 mg liver was weighed for GSH assay and the rest was homogenized for the total protein, MDA and GST level determination.

Biochemical Analyses

The total protein for both the serum and liver was determined using Bradford's method (1976). Serum ALT and liver GST levels were estimated according to Reitman and Frankel (1957), and Habig *et al.* (1974), respectively. Liver GSH and MDA levels were determined following the method of Hissin and Hilf (1976) and Ledwozyw *et al.* (1986), respectively.

Histology

The liver sections that were fixed in 10% formalin solution were processed for the normal histological section. The tissue samples were sectioned, stained with H & E and examined under light microscope for observation of morphological abnormality.

Statistical Analysis

The mean values obtained in the biochemical analyses were analyzed for the statistical difference using the Student's *t*-test.

TABLE 1

The effect of roselle or *H. sabdariffa* on the total protein level in the serum and liver.

Treatment group	Serum	Total protein (mg/ml) liver
Untreated (control)	3.01 ± 0.01	18.42 ± 0.28
Paracetamol (1000 mg/kg)	1.68 ± 0.01*	15.68 ± 0.34*
500 mg/kg roselle & paracetamol	3.35 ± 0.02**	15.58 ± 0.03
1000 mg/kg roselle & paracetamol	3.93 ± 0.10**	18.88 ± 0.60**
500 mg/kg roselle	3.62 ± 0.06*	18.43 ± 0.22
1000 mg/kg roselle	4.24 ± 0.19*	23.35 ± 0.10*

The data are presented as the mean ± SEM of 6 animals. *Significantly different compared to the untreated group (control), $p < 0.05$. **Significantly different compared to the group given paracetamol, $p < 0.05$.

RESULTS AND DISCUSSION

Total Protein Analyses

Table 1 shows that the treatment of 1000 mg/kg PCM to the rats significantly reduced 44% and 15% of the total protein in the serum and liver, respectively, as compared to the untreated rats. Similar observations were also reported by Lu (1985) who observed that the metabolism of excess PCM in the liver led to the formation of excess free radicals and reactive metabolite, N-acetyl-p-benzoquinimine (NAPQI) that formed covalent bond with the protein thiol group which eventually disrupted the synthesis of the protein and reduced the total protein level. When the right dose of the PCM was taken, NAPQI was detoxified by glutathione S-transferase into mercapturic acid, which was then excreted via urine to avoid it from affecting protein synthesis.

The results also showed that the total protein reductions in the PCM-induced hepatotoxicity rats seemed to be counteracted by giving high and low dosages of *H. sabdariffa* to the rats after the PCM treatment (Table 1). Similar observations

were also made by Onyenekwe *et al.* (1999) who discovered that the addition of *H. sabdariffa* calyx infusion to the hypertensive rats had increased the total protein in the serum and liver. Interestingly, the addition of *H. sabdariffa* to the untreated rats also increased the total protein in both the serum and liver (Table 1). This increase is actually important in forming and repairing new and damaged cells and tissues, respectively.

Serum Alanin Transaminase Analyses

The increased level of serum ALT is normally used as an indicator of liver damage. During liver damage, cell lyses normally cause higher distribution of ALT in the liver cytoplasm which will eventually lead to the spill of ALT into the blood circulation (Galteau *et al.*, 1980). In this study, the PCM-treated rats showed 74.5% increase of serum ALT as compared to the control, indicating hepatotoxicity (Table 2). When *H. sabdariffa* was given to these rats after the PCM injection, a significant reduction of elevated ALT level was observed (Table 2). In more specific,

TABLE 2
The effects of roselle or *H. sabdariffa* on the ALT, GST, MDA and GSH levels.

Treatment Group	ALT (IU/l)	GST (IU/mg)	MDA (nmol/mg)	GSH (ug/g)
Untreated (control)	71.86 ± 5.22	0.70 ± 0.29	0.12 ± 0.02	0.28 ± 0.02
Paracetamol (1000 mg/kg)	125.37 ± 1.64*	12.38 ± 0.37*	8.66 ± 0.74*	0.056 ± 0.008*
500 mg/kg roselle & paracetamol	119.51 ± 1.85**	2.05 ± 0.33**	6.55 ± 0.34**	0.073 ± 0.005
1000 mg/kg roselle & paracetamol	81.55 ± 2.08**	1.15 ± 0.06**	4.96 ± 0.29**	0.21 ± 0.009**
500 mg/kg roselle	82.21 ± 2.58	2.74 ± 0.17*	0.35 ± 0.02*	0.26 ± 0.010
1000 mg/kg roselle	96.17 ± 3.41*	2.00 ± 0.17*	0.34 ± 0.02*	0.28 ± 0.009

The data are presented as the mean ± SEM of 6 animals. *Significantly different compared to the untreated group (control), p<0.05. **Significantly different compared to the group given paracetamol, p<0.05

at 1000 mg/kg, *H. sabdariffa* gave a larger reduction of ALT level as compared to the lower dosage of *H. sabdariffa*. In another study, Ali *et al.* (2003) found that feeding *H. sabdariffa* extract before the PCM treatment also resulted in a similar effect. Intriguingly, feeding high dose of *H. sabdariffa* to untreated rats significantly increased the ALT level although much lower compared to the PCM-treated rats (Table 2). This increase, however, does not change the morphology of the liver (Fig.1). Other study has also shown a similar observation when *H. sabdariffa* (at 250 mg/kg in 3, 5, 10 and 15 doses) was given to normal rats (Akindahunsi & Olaleve, 2003), in which the increase in ALT was not followed by pathological changes in the liver and the heart, when both the organ sections were observed under microscope. One report has suggested that only excessive doses of *H. sabdariffa* given for a relatively long period could have a deleterious effect to the rats, particularly on their testes (Ali *et al.*, 2005).

Liver Glutathione Analyses

Hepatotoxicity induces depletion of GSH (Ohta *et al.*, 1995), as higher amount of GSH is required to detoxify the toxic compounds. In this study, GSH level was significantly reduced by 80% in the PCM-treated rats compared to the control group (see Table 2). It was reduced due to the increased GSH requirement in conjugating with free radicals and NAPQI (PCM reactive metabolite) in order to detoxify it (Wendel *et al.*, 1979). The present study have also demonstrated that the post-treatment with *H. sabdariffa* at 500 mg/kg increased 31% of GSH level observed in the PCM induced-hepatotoxicity rats and increased 275% (i.e. almost similar to the level of untreated rats) when given 1000 mg/kg of *H. sabdariffa* (Table 2). A similar observation was also demonstrated in another study when the pre-treatment of *H. sabdariffa* extract was given to a PCM-treated mouse (Liu *et al.*, 2010). It is important to note that the treatments of both low and high doses of *H. sabdariffa* to

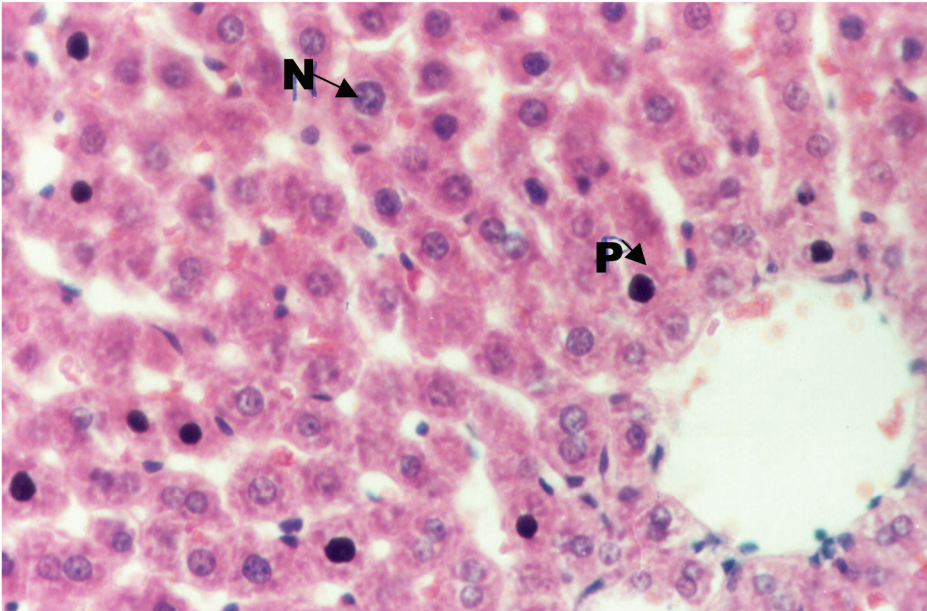


Fig.1: Liver of the PCM-induced animals (400x). The normal and picnotic nucleus are indicated by the arrow. N = nucleus; P = picnotic nucleus

the untreated rats did not increase the GSH level (Table 2). In fact, it was found to have been maintained at almost similar level of the normal rats. This finding suggests that there are no bioactive compounds in *H. sabdariffa* that stimulate the synthesis of GSH; instead, it is possible that the *H. sabdariffa* aqueous extract itself contains bioactive compound which removes PCM toxic metabolites, and thus increases the reduced GSH level of affected animals. In other studies, the bioactive compounds that have been confirmed to scavenge free radicals in *H. sabdariffa* include protocatechuic acid and anthocyanin (Tseng *et al.*, 1996; Wang *et al.*, 2000).

Liver Glutathione S-transferase Analyses

In this study, the liver GST activity was tremendously increased in the group

treated with PCM (Table 2). This elevated level was anticipated as it was one of the mechanisms to detoxify the high dosage of PCM given. Chasseaud (1976) showed that GST catalysed the conjugation of GSH with the electrophilic groups of other toxic compounds. This reaction neutralized the toxic compounds and induced them to easily dissolve in water so as to be easily secreted into urine or faeces. Meanwhile, supplements of *H. sabdariffa* at low and high doses after the PCM treatment were found to have significantly reduced the elevated GST level (Table 2). This result confirms the above statement (in *Liver Glutathione Analyses*) that the bioactive compounds in *H. sabdariffa* help to remove undesired PCM toxic metabolites, and thus, reduce the burden of GST to detoxify them and the elevated GST level in the

PCM-treated animals. However, feeding *H. sabdariffa* at both doses to the untreated rats also increased the GST level, and this is similar to the reaction of the PCM-treated rats. Nonetheless, the increase was not alarming and it was most probably because a few chemical constituents in *H. sabdariffa* at 500 and 1000 mg/kg animal were too high and needed to be removed from the liver and thus caused the increase in the GST level.

Liver Malonaldehyde Analyses

MDA is one of the products of lipid peroxidation. By determining the MDA level, the stage of lipid peroxidation could be estimated. Normally, an elevated level of MDA indicated a high lipid peroxidation activity and reduced the level of GSH (Albano *et al.*, 1983). The results showed that the treatment of PCM to the rats drastically increased the MDA level (Table 2), confirming the high lipid peroxidation activity in the affected liver. Interestingly, this extreme elevated level was counteracted by giving *H. sabdariffa* in both doses. The supplement of both high and low doses of *H. sabdariffa* to the untreated rats significantly increased the MDA level as compared to the control group, although this was at much lower level than the PCM-treated rats. It is intriguing to discover that although *H. sabdariffa* can reduce the lipid proxidation caused by over-dosage PCM, it can also cause lipid peroxidation in the untreated rats. Even though the exact reasons for these two effects are not known, these are probably due to the various effects of the

many chemical constituents that are present in the crude extract of the plant.

Based on the results of both GST and MDA, future studies must be carried out to determine the right dosage of *H. sabdariffa* consumption and the length in which the supplement should be taken so as not to deteriorate the general effects of *H. sabdariffa* that prevent the progression of acute liver injury induced by PCM.

Histological Observation

In this study, the liver of the hepatotoxicity-induced animals showed many picnotic nuclei (Fig. 1), suggesting that the liver cell were suffering from degeneration of the protein structure. In contrast, the liver of hepatotoxicity-induced animals that were given *H. sabdariffa* showed a normal histology that was similar to the untreated animals (Fig.2). From these observations, it was suggested that *H. sabdariffa* might play a role in preventing further liver degeneration in the PCM-treated animals. In other studies, it was observed that the supplement of natural pigments of *H. sabdariffa* (anthocyanins) before the PCM treatment restored liver damage to normal as well (Ali *et al.*, 2003).

Interestingly, when given *H. sabdariffa* alone, the rats' liver showed no pathological changes in spite of the increases in the animals' GST, ALT and MDA levels. It is a relief that the liver of these rats showed normal morphology; however, an appropriate dose of *H. sabdariffa* needs to be determined so as to avoid any side effect, if

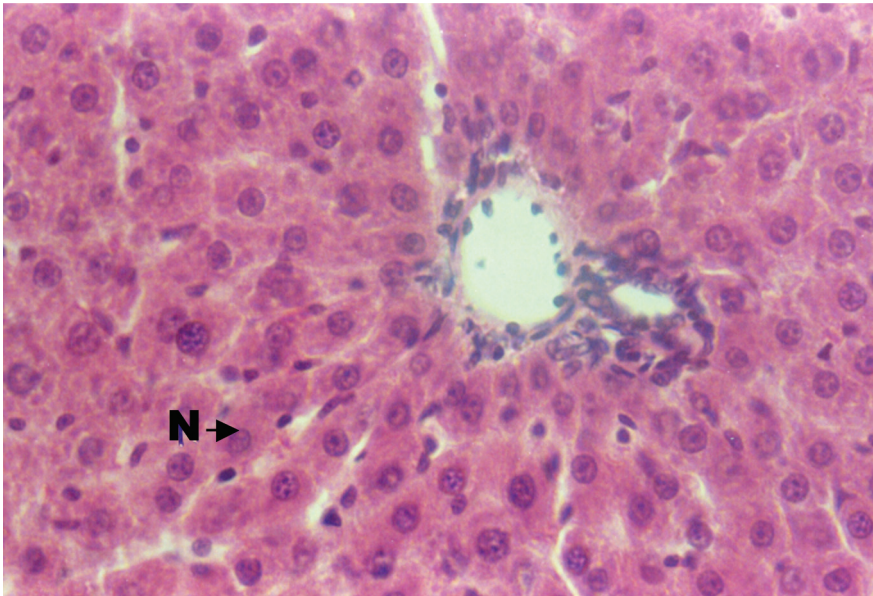


Fig.2: Liver of the untreated (control) animals stained with H & E (400x). The normal nucleus is indicated by the arrow. N = nucleus

the plant is to be consumed daily for a long period of time.

CONCLUSION

This study has shown that the post-treatment of *H. sabdariffa* aqueous extracts to PCM-induced hepatic toxicity rats prevents progression of acute liver injury by improving lipid peroxidation, reducing the level of GSH and increasing the level of GST and ALT caused by the PCM treatment. This preventive action could also be seen when the pathological changes of the liver in the PCM-treated animals were improved by giving them the post-treatment of *H. sabdariffa*. However, the consumption of unnecessarily high dosage of *H. sabdariffa* for long duration of time should be taken with caution.

ACKNOWLEDGEMENTS

The authors would like to thank Ms. Mona Ali from Monrose Company Sendirian Berhad for kindly providing the powdered roselle.

REFERENCES

- Adaramoye, O., Ogungbenro, B., Anyaegbu, O., & Fafunso, M. (2008). Protective effects of extracts of *Vernonia amygdalina*, *Hibiscus sabdariffa* and vitamin C against radiation-induced liver damage in rats. *Journal of Radiation Research*, *49*, 123-131.
- Akindahunsi A. A., & Olaleye, M. T. (2003). Toxicological investigation of aqueous-methanolic extract of the calyces of *Hibiscus sabdariffa* L. *Journal of Ethnopharmacology*, *89*, 161-164.
- Albano, E., Poli G., Chiarpotto, E., Biasi, F., & Dianzani, M. U. (1983). Paracetamol-stimulated

- lipid peroxidation in isolated rat and mouse hepatocytes. *Chemical Biological Interactions*, *47*, 249-263.
- Ali, B. H., Mousa, H. M., & el-Mougy, S. (2003). The effect of a water extract and anthocyanins of *Hibiscus sabdariffa* L on paracetamol-induced hepatotoxicity in rats. *Phytotherapy Research*, *17*, 56-59.
- Ali, B. H., Al Wabel, N., & Blunden, G. (2005). Phytochemical, pharmacological and toxicological aspects of *Hibiscus sabdariffa* L.: a review. *Phytotherapy Research*, *19*, 369-375.
- Ajay, M., Chai, H. J., Mustafa, A. M., Gilani, A. H., & Mustafa, M. R. (2007). Mechanisms of the anti-hypertensive effect of *Hibiscus sabdariffa* L. calyces. *J. of Ethnopharmacology*, *109*, 388-393.
- Amin, A., & Hamza, A. A. (2005). Hepatoprotective effects of *Hibiscus*, *Rosmarinus* and *Salvia* on azathioprine-induced toxicity in rats. *Life Sciences*, *77*, 266-278.
- Azuine, M. A., Kayal, J. J., & Bhide, S. V. (1992). Protective role of aqueous turmeric extract against mutagenicity of direct-acting carcinogens as well as benzo-pyrene-induced genotoxicity and carcinogenicity. *Cancer Research Clinical Oncology*, *118*, 447-452.
- Bradford, M. M. (1976). A rapid and sensitive method for the quantitation of microgram quantities of protein utilizing the principle of protein-dye binding. *Analytical Biochemistry*, *72*, 248-254.
- Chasseaud, L. F. (1976). *Glutathione metabolism and function: GSH conjugates and mercapturic acids*. New York: Raven Press.
- el-Saadany, S. S., Sitohy, M. Z., Labib, S. M., & el-Massry, R. A. (1991). Biochemical dynamics and hypocholesterolemic action of *Hibiscus sabdariffa* (Karkade). *Nahrung*, *35*, 567-576.
- Galteau, M. M., Morin, C., & Seist, G. (1980). Interpretation of laboratory tests: the example of drug effects on aminotransferases. In G. Seist (Ed.), *Developments in Clinical Biochemistry, Vol. 2: Drug Effects on Laboratory Test Results*. (p. 67). Vandoeuvre-Les-Nancy: Martinus Nijhoff.
- Habig, W. H., Pabst, M. J., & Jakoby, W. B. (1974). The first enzymatic step in mercapturic acid formation. *The Journal of Biological Chemistry*, *249*, 7130-7139.
- Herrera-Arellano, A., Flores-Romero, S., Chavez-Soto, M. A., & Tortoriello, J. (2004). Effectiveness and tolerability of a standardized extract from *Hibiscus sabdariffa* in patients with mild to moderate hypertension: a controlled and randomized clinical trial. *Phytomedicine*, *11*, 375-82.
- Hissin, P. J., & Hilf, R. (1976). A fluorometric method for determination of oxidized and reduced glutathione in tissues. *Analytical Biochemistry*, *74*, 214-226.
- Ledwozyw, A., Michalak, J., Stepie, A., & Kadziolka, A. (1986). The relationship between plasma triglycerides, cholesterol, total lipids and lipid peroxidation products during human atherosclerosis. *Clinica Chimica Acta*, *155*, 275-284.
- Lin, W. L., Hsieh, Y. J., Chou, F. P., Wang, C. J., Cheng, M. T., & Tseng, T. H. (2003). *Hibiscus* protocatechuic acid inhibits lipopolysaccharide-induced rat hepatic damage. *Archives of Toxicology*, *77*, 42-47.
- Liu, L. C., Wang, C. J., Lee, C. C., Su, S. C., Chen, H. L., Hsu, J. D., & Lee, H. J. (2010). Aqueous extract of *Hibiscus sabdariffa* L. decelerates acetaminophen-induced acute liver damage by reducing cell death and oxidative stress in mouse experimental models. *Journal of the Science of Food and Agriculture*, *90*, 329-337.
- Liu, C. L., Wang, J. M., Chu, C. Y., Cheng, M. T., & Tseng, T. H. (2002). *In vivo* protective effect of

- protocatechuic acid on tert-butyl hydroperoxide-induced rat hepatotoxicity. *Food and Chemical Toxicology*, 40, 635-641.
- Lu, F. C. (1985). *Basic toxicology*. California: Hemisphere.
- Mat Isa A., Md Isa P. M., & Abd Aziz, R. (1985). Chemical analysis and roselle processing (*Hibiscus sabdariffa* L.). *MARDI Research Bulletin*, 13, 68-74.
- Morton, J. F. (1987). *Fruits of Warm Climates*. Florida: Morton.
- Ohta, Y., Sasaki, E., Nishida, K., Kobayashi, T., Nagata, M., & Ishiguro, I. (1995). Preventive effect of Dai-saiko-to (Da-Chai-Hu-Tang) extracts in disrupted hepatic active oxygen metabolism in rats with carbon tetrachloride-induced liver injury. *American Journal Chinese Medicine*, 23, 53-64.
- Olaleye, M. T., & Rocha, B. T. (2008). Acetaminophen-induced liver damage in mice: effects of some medicinal plants on the oxidative defense system. *Experimental and Toxicologic Pathology*, 59, 319-327.
- Onyenekwe, P. C., Ajani, E. O., Ameh, D. A., & Gamaniel, K. S. (1999). Antihypertensive effect of roselle (*Hibiscus sabdariffa*) calyx infusion in spontaneously hypertensive rats and a comparison of its toxicity with that in Wistar rats. *Cell Biochemistry Function*, 17, 199-206.
- Reitman, S., & Frankel, S. (1957). Calorimetric method for the determination of serum glutamic oxalacetic and glutamic pyruvic transaminases. *American Journal of Clinical Pathology*, 28, 56-60.
- Tseng, T. H., Wang, C. J., Kao, E. S., & Chu, H. Y. (1996). Hibiscus protocatechuic acid protects against oxidative damage induced by tert-butylhydroperoxide in rat primary hepatocytes. *Chemico-Biological Interactions*, 101, 137-148.
- Wang, C. J., Wang, L. W., Lin, W. L., Chu, C. Y., Chou, F. P., & Tseng, T. H. (2000). Protective effect of Hibiscus anthocyanins against tert-butyl hydroperoxide-induced hepatic toxicity in rats. *Food and Chemical Toxicology*, 38, 411-416.
- Wendel, A., Feurstein, S., & Konz, K. (1979). Acute paracetamol intoxication of starved mice leads to lipid peroxidation *in vivo*. *Biochemistry Pharmacology*, 28, 2055-2057.